Effect of Botulinum Toxin Type A on Movement-Associated Rhytides Following CO_2 Laser Resurfacing

TINA B. WEST, MD, AND TINA S. ALSTER, MD

Washington Institute of Dermatologic Laser Surgery, Washington, DC

BACKGROUND. **Many patients who undergo CO_2 laser resurfacing for correction of rhytides experience recurrence of movement-associated wrinkles within 6 to 12 months following the laser procedure.**

OBJECTIVE. **The purpose of this study was to evaluate the effect of botulinum toxin type A (*Botox*) injections on movement-associated rhytides following cutaneous laser resurfacing.**

METHODS. **Forty patients who had received full face CO_2 laser resurfacing for the treatment of facial rhytides were randomized to receive *Botox* injections to the glabella, forehead or lateral canthal regions or to receive no additional treatment (control group). Clinical and photographic assessments were performed at baseline and at 3, 6 and 9 months.**

RESULTS. **Enhanced and more prolonged correction of forehead, glabellar and/or lateral canthal rhytides was observed in patients treated with *Botox* injections postoperatively compared to non-*Botox* treated control patients.**

CONCLUSION. **The use of botulinum toxin type A following cutaneous CO_2 laser resurfacing results in prolonged correction of movement-associated rhytides. It is advised that patients receive information regarding the benefits of maintenance therapy with botulinum toxin as part of their routine preoperative education.**

IN RECENT YEARS, carbon dioxide (CO_2) laser resurfacing has been used to reduce the signs of photoaging. The areas shown to be the most amenable to laser treatment include the periorbital and perioral regions.[1–3] However, many patients who undergo CO_2 laser resurfacing for correction of rhytides experience recurrence of movement-associated wrinkles within 6 to 12 months following the laser procedure.[3]

Cosmetic denervation (reversible paralysis) using intramuscular botulinum toxin type A (*Botox*, Allergan, Inc., Irvine, CA) injection has been shown to reduce movement-associated rhytides.[4–7] *Botox* is a potent neurotoxin that is produced by Clostridium botulinum. The toxin inhibits release of acetylcholine from presynaptic neurons at the neuromuscular junction. Reversible paralysis typically persists for 3 to 6 months in the treated areas.

The purpose of this investigation was to evaluate the effect of *Botox* injections on movement-associated rhytides following cutaneous laser resurfacing. It was postulated that reversible paralysis of involved facial musculature would prevent the recurrence and/or severity of movement-associated rhytides after CO_2 laser resurfacing.

Address correspondence and reprint requests to: Tina S. Alster, MD, 2311 M Street, N.W. Suite 200, Washington, D.C. 20037.

Materials and Methods

Following informed consent, 40 patients (age range, 35–72 years; mean, 55 years) who had received full-face CO_2 laser resurfacing for the treatment of facial rhytides within the preceding 3 months were enrolled in the study. A high energy, pulsed CO_2 laser (*Ultrapulse*, Coherent Corp., Palo Alto, CA) was used in all cases by a single operator (TSA) at 300 mJ and 60 W through a 5–8 mm square computer generated scanner (CPG) with a density of 6 to treat the full face and/or periorbital region. Adjacent nonoverlapping scans were placed over the treatment areas and partially-desiccated tissue was removed with saline-soaked gauze after each laser pass. The number of laser passes ranged from 2 to 4 depending upon the location and severity of rhytides. Patients were then randomly assigned to receive treatment with botulinum toxin or to serve as controls.

Twenty patients received botulinum toxin type A to the glabella (35 units, n = 12), forehead (20 units, n = 5) or lateral canthal regions (18 units, n = 3) 1 to 3 months (average 1.8 months) following the resurfacing procedure. All injections were delivered using identical technique by a single physician (TBW). Prior to injection, the area to be treated was cleaned with alcohol. The specified amount of botulinum toxin was then injected at multiple sites appropriate to the treatment area, using a 1-cc syringe equipped with a 30-gauge needle. Postoperatively, all patients were instructed to remain upright and to avoid exercise or manipulation of the treated area for 6 hours. No air travel was permitted for 48 hours after injection. *Botox* treatments were repeated when muscle activity was noted to reappear in the treated areas (mean = 4.5 months). Return of full muscle activity

ISSN: 1076-0521/99/ • Dermatol Surg 1999;25:259–261

Figure 1. A) 55-year-old woman before CO_2 laser resurfacing; B) 3 months after resurfacing (baseline); and C) 6 months later without any additional treatment showing recurrence of movement-associated rhytides.

was not necessary before retreatment was performed. The remaining 20 patients received no additional treatment and served as a control group.

Clinical assessments using comparative photography with identical digital camera (*Mirror Image*, Virtual Eyes, Kirkland, WA), patient positioning, and lighting techniques were made by 2 blinded nurse assessors at baseline (1–3 months postoperatively, mean 2.5 months) and at 3, 6, and 9 months after study initiation. A numeric scoring system was used to assess the severity of rhytides: 0 = no rhytides, 1 = mild rhytides (<1 mm deep), 2 = moderate rhytides (1–2 mm deep), 3 = severe rhytides (>2 mm deep). The mean of three scores by each assessor was determined at each visit for every patient.

Results

Enhanced and more prolonged correction of forehead, glabellar and/or lateral canthal rhytides was observed in patients treated with *Botox* injections postoperatively compared to non-*Botox*-treated control patients (Figures 1 and 2). All *Botox*-treated patients required 1 to 2 injection sessions (average 1.7) over the 9-month course of the study (Figure 3). The average clinical score at 9 months was 1.2 (mild to moderate rhytides) for control patients versus 0.5 (none to mild rhytides) for botulinum toxin-treated patients (Figure 4). All treatment locations appeared to be equally responsive to *Botox* injections. Side effects of *Botox* were limited to transient ecchymoses at the injection sites in 3 patients, with complete resolution within 5 days. No other adverse effects, including eyelid or brow ptosis, were observed.

Discussion

Carbon dioxide laser resurfacing has been proven effective in reversing the cutaneous stigmata associated with photoaging through epidermal ablation, collagen shrinkage, stimulation of neocollagenesis, dermal reorganization, and regeneration of cellular organelles and intercellular attachments.[1–3,8] Immediately following the laser resurfacing procedure, coarse movement-associated rhytides as well as fine rhytides associated with photoaging are often resolved. Studies have shown clinical improvement of non-movement-associated rhytides to be as high as 80–94%, whereas move-

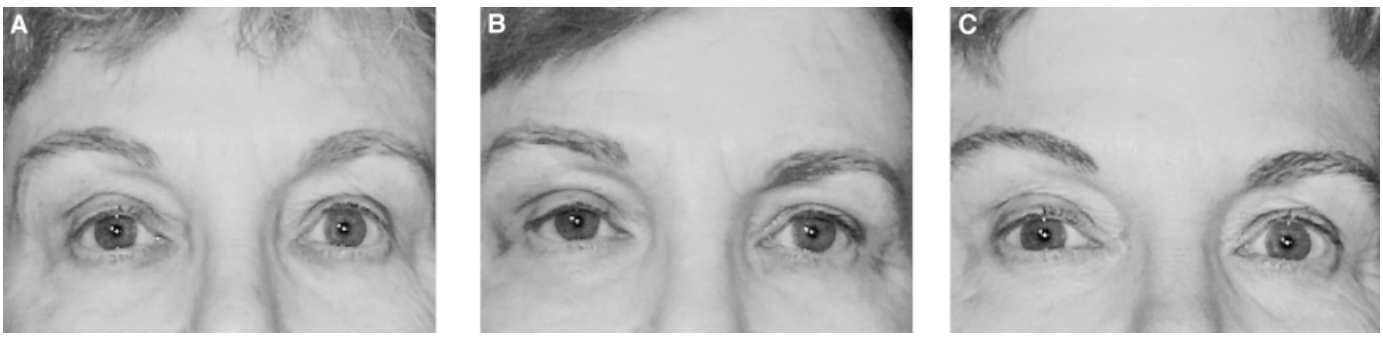

Figure 2. A) 55-year-old woman before CO_2 laser treatment; B) 2 months after resurfacing with full brow movement and transverse line (baseline); and C) 9 months later after 2 *Botox* injections (postoperative months 2 and 6) showing prolonged correction of movement-associated rhytides.

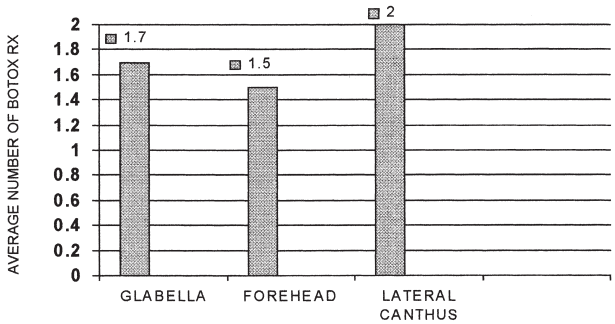

Figure 3. Anatomical locations and number of *Botox* treatments.

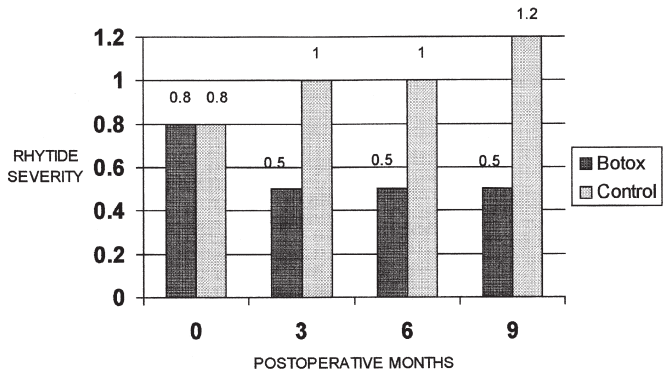

Figure 4. Clinical assessment scores.
Scale: 0 = no rhytides, 1 = mild rhytides (<1 mm deep), 2 = moderate rhytides (1–2 mm deep), 3 = severe rhytides (>2 mm deep)

ment-associated rhytides average improvements that typically range 45–85%.[1,2] Extended postoperative analysis of patients following CO_2 laser resurfacing has shown progressive improvement of skin tone and texture for at least 12 months, presumably due to continued collagen remodeling and angiogenesis.[9] However, rhytides that are associated with repetitive contraction of underlying facial musculature generally recur within 6 to 12 months.[9,10]

Our study confirms that worsening of movement-associated rhytides occurs within 6 to 12 months after the resurfacing procedure, due to continued muscle use. In patients who receive injections with botulinum toxin Type A, reversible paralysis of the implicated musculature is achieved with subsequent prolonged correction of movement-associated rhytides. We did not include a study arm consisting of treatment with botulinum toxin alone because all patients who entered our study were candidates for skin resurfacing, based on findings typical of photoaging. It is clear that botulinum toxin injections result in improvement or disappearance of movement-associated rhytides; however, the use of botulinum toxin has not previously been demonstrated to delay or prevent the recurrence of rhytides following laser skin resurfacing.

Conclusions

The use of botulinum toxin Type A following cutaneous CO_2 laser resurfacing results in prolonged correction of movement-associated rhytides. It is advised that patients receive information regarding the benefits of maintenance therapy with botulinum toxin as part of their routine preoperative education.

References

1. Alster TS, Garg S. Treatment of facial rhytides with a high-energy pulsed carbon dioxide laser. Plast Reconstr Surg 1996;98:791–4.
2. Fitzpatrick RE, Goldman MP, Satur NM, Tope WD. Pulsed carbon dioxide laser resurfacing of photoaged facial skin. Arch Dermatol 1996;132:395–402.
3. Alster TS. Laser resurfacing of rhytides. In: Alster TS. Manual of Cutaneous Laser Techniques. Philadelphia: Lippincott-Raven Publishers, 1997:104–22.
4. Carruthers J, Carruthers A. Treatment of glabellar frown lines with C botulinum A toxin. J Dermatol Surg Oncol 1992;18:17–21.
5. Carruthers A, Kiene K, Carruthers J. Botulinum A exotoxin use in clinical dermatology. J Am Acad Dermatol 1996;34:788–97.
6. Garcia A, Fulton JE. Cosmetic denervation of the muscles of facial expression with botulinum toxin: a dose-response study. Dermatol Surg 1996;22:39–43.
7. Klein AW. Cosmetic therapy with botulinum toxin. Dermatol Surg 1996;22:757–9.
8. Ratner D, et al. Pilot ultrastructural evaluation of human preauricular skin before and after high-energy pulsed carbon dioxide laser treatment. Arch Dermatol 1998;134:582–7.
9. Nanni CA, Alster TS. Cutaneous carbon dioxide laser resurfacing: long-term follow-up of 300 patients. Lasers Surg Med 1997;suppl 9:39.
10. Alster TS. Preoperative preparation for CO_2 laser resurfacing. In: Coleman WP, Lawrence N, eds. Skin Resurfacing. Baltimore: Williams & Wilkins, 1998:171–9.